

**CASE REPORT**

# AUTOGENOUS TOOTH TRANSPLANTATION: A REPORT OF TEN CASES & REVIEW OF LITERATURE



**U.S.Pal\* MDS; Nimisha Singh\* MDS; Laxman R Malkunje\* MDS; Rakesh Kumar Yadav\*\*MDS; Mayank Singh # MDS**

\* Dept of Oral and Maxillofacial Surgery K.G. Medical University, Lucknow \*\* Dept of Endodontics, K.G. Medical University, Lucknow # Dept of Prosthodontics, K.G. Medical University, Lucknow

**Address for correspondence:** Dr. U.S.Pal Associate Professor, Dept of Oral and Maxillofacial Surgery K.G. Medical University, Lucknow, India.

Email: [uspalkgmc@yahoo.co.in](mailto:uspalkgmc@yahoo.co.in)

**Abstract :** Autogenous tooth transplantation, or autotransplantation, is a promising procedure for recovering the occlusal function of lost teeth. Once thought to be experimental, autotransplantation has achieved high success rates and is an excellent option for tooth replacement. Autotransplantation is now a common procedure in dentistry for replacing a missing tooth especially in children and adolescents where implants and other prosthetic replacements are contraindicated for various reasons. Although the indications for autotransplantation are narrow, careful patient selection coupled with an appropriate technique can lead to exceptional esthetic and functional results. In this article we present a report of ten cases of autotransplantation and highlight that tooth autotransplantation is still a very useful method for replacing missing teeth.

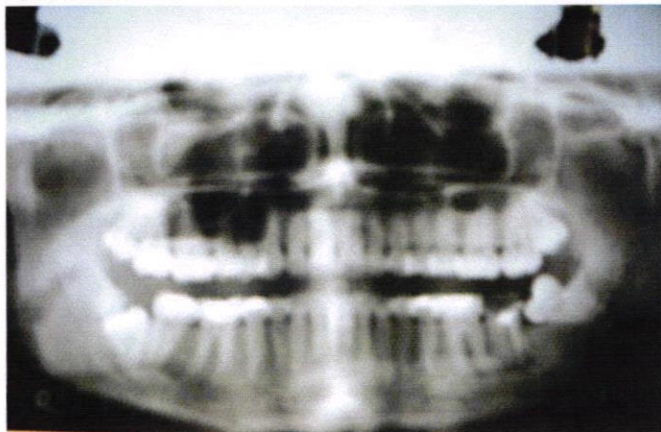
## Introduction

More than 95% of immediately transplanted teeth are reported to survive and function like normal teeth, even when root formation is not achieved(1). The indications for immediate tooth transplantation are limited, because both the healthy donor tooth and a healthy recipient site must be available in a patient at the same time.

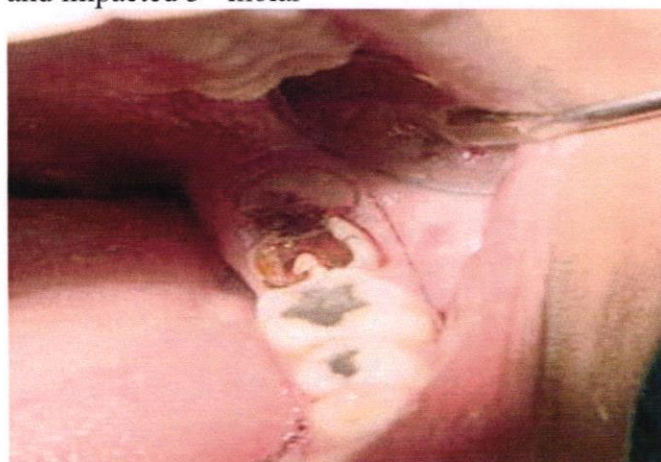Autogenous tooth transplantation or dental autotransplantation is defined as the transplantation of impacted or erupted teeth from their original sites into extraction sockets or surgically prepared recipient sites in the same individual. It is a promising procedure for recovering the occlusal function of lost teeth when suitable donor teeth are available(2) and is generally indicated in cases of dental agenesis, nontreatable root fractures, and prematurely lost teeth from trauma, caries disease, or periodontal causes.(3) Transplanted tooth ensure

maintenance of the alveolar bone and they can also be moved orthodontically(4).

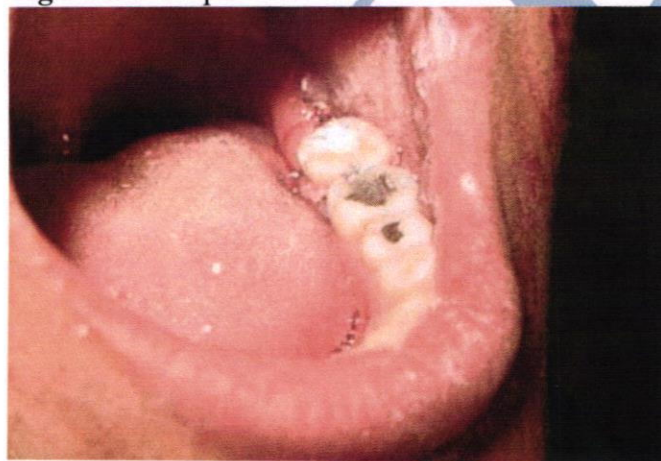Examination of available literature regarding the prognosis of autogeneous dental transplants clearly demonstrates that the rate of success varies with the surgical technique, surgeon's attention and skill, and patient concern about the procedure. The success rate of autogenously transplanted teeth ranges from 68% to 96%.(2,5) Nevertheless, a number of preoperative, transoperative, and postoperative factors might interfere with the prognosis of cases of autotransplantation, such as the age of the patient, root development stage, type of tooth transplanted, periodontal ligament and pulp tissue vitality, extra-alveolar time and storage medium of the donor tooth while the recipient site is prepared, transplanting the tooth at the right stage of development (with maximum root formation, but before closure of the apex has occurred), damage to Hertwig's epithelial root sheath during extraction, characteristics of the



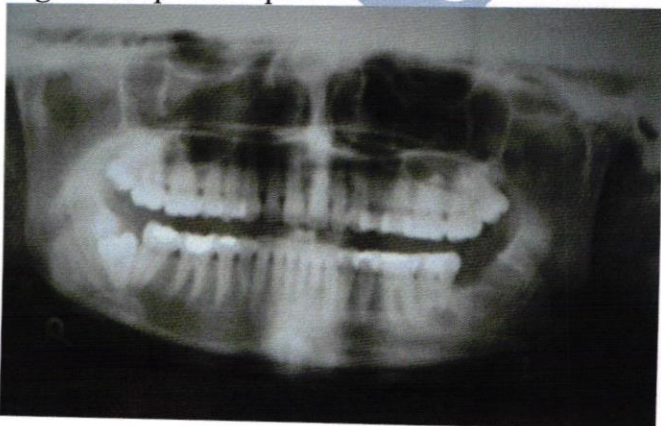**Fig.1** Preoperative OPG showing carious 2<sup>nd</sup> molar and impacted 3<sup>rd</sup> molar



**Fig.2** Intraoral picture



**Fig.3** Postoperative picture



**Fig.4** Postoperative OPG

recipient site, and the use of a nonrigid splinting technique.(6) Preoperative antibiotics are helpful.

The most frequently transplanted teeth are the permanent upper cuspids into their correct site and impacted third molars into first or second molar sockets. Autogenous tooth transplantation was first well documented in 1954 by M.L. Hale. The major principles of his technique are still followed today.(7) The science of autotransplantation has progressed, as evidenced by the high success rates reported in studies over the past decade.(8, 9, 10) Our study demonstrate that autotransplantation is a viable option for tooth replacement for carefully selected patients.

#### **Materials and methods:**

We performed autogenic tooth transplant in 10 patients at department of Oral & Maxillofacial Surgery, K.G. Medical University. 7 were male and 3 female, ranging in age from 14 to 23 years. All patients were in good health and routine examination demonstrated no systemic or local contraindications to surgical treatment. For the clinical assessment of the case, intraoral radiographs were taken to get information about the tooth's size, shape, and length, as well as about the surrounding periodontal structures.

Once sufficient anesthesia was obtained, preparation of recipient site was done. The tooth at the recipient site was extracted and the recipient socket prepared. Occlusal and periapical radiographs of the donor tooth were used to determine its labiolingual and mesiodistal dimensions. Next, the donor tooth was carefully removed to ensure minimal trauma to the periodontal ligament. When the donor tooth was unerupted, extraction involved flap elevation, bone removal, and gentle removal of the follicle from around the crown. Traumatic injury to the root surface of the donor tooth was avoided. Once removed, the donor tooth was handled as little as possible. The tooth was then placed in the prepared recipient socket. Minimal delay between extraction and transplantation was kept to ensure maintenance of periodontal membrane vitality. If further adjustment of the recipient socket was required, the donor tooth was stored in its original socket.

After transplantation, occlusion was checked and, if needed, adjusted using a high-speed finishing bur. The tooth was kept in slight infraocclusion to allow it to erupt into proper occlusion over the next few months. When proper positioning was obtained, the tooth was stabilized with a suture splint for 2 to 3 weeks.

Post-operatively patients were instructed to take soft diet and to avoid mastication on the transplant. Patients were also instructed to maintain optimal oral hygiene. Postoperative antibiotics were prescribed for five days.

### Results:

Each of the ten transplanted teeth clinically appeared to grow firmer with the passage of time. No signs of inflammation were observed during the healing period. Also, no operative pain or other complications were noticed. Two weeks after transplantation, no signs of tenderness or pain were recorded, but the teeth exhibited mobility. By the end of the month, all the teeth and the surrounding gingiva appeared indistinguishable from their neighbors except one where the surrounding gingiva was inflamed. After 6 months and thereafter all the transplanted teeth were firm in their sockets, and the gingival appearance was excellent except one which was having mobility and showing periapical radiolucency and had to be removed.

### Discussion:

Between 1950 and 1955, detailed surgical techniques for the transplantation of developing teeth, particularly from the third molar to the first molar position, have been described and well documented by Apfel (11, 12) Fong,(13) Hale,(14) and Clark.(15) According to these authors, the recipient site should have sufficient dimensions, sound periodontal support, and no acute inflammation. Minimal handling of the transplant is important, and great care should be taken not to denude or even touch any of the Hertwig's root sheath or exposed pulpal tissue. They also pointed out that third molars should be developed beyond their bifurcation to be successfully transplanted. According to Apfel and Fong, (11-13) the optimal root development for transplantation is 2 to 3 mm of root apical to the crown, whereas Hale and Clark (14, 15) recommend that at least 3 to 5 mm of root formation be present to permit optimum development to continue. In 1980, Northway and Konigsberg' presented a comprehensive review of the subject of autogenic tooth transplantation, and they also recommended that at least 3 to 5 mm of root formation be present, the root being between a third to three quarters developed.

In cases of dental transplantation, it has been reported that the donor tooth should ideally present one third to three fourths of root formation to allow normal root development (apexogenesis) and revascularization of the pulp tissue.(2, 5) Kallu et al.,(2) in a descriptive retrospective study of

autogenous tooth transplantations, observed that only 92 out of 273 autotransplanted teeth maintained pulp vitality after the procedure and recommended that donor teeth with complete root formation be endodontically treated after transplantation.

The literature reports excellent success rates following tooth transplantation when the appropriate protocol is followed. Andreasen<sup>1</sup> found 95% and 98% long-term survival rates for incomplete and complete root formation of 370 transplanted premolars observed over 13 years. Lundberg and Isaksson<sup>(10)</sup> had success in 94% and 84% of cases for open and closed apices respectively in 278 autotransplanted teeth over 5 years. Kugelberg<sup>(16)</sup> achieved success rates of 96% and 82% for 45 immature and mature teeth transplanted into the upper incisor region over 4 years. Cohen<sup>(8)</sup> showed success in the ranges of 98-99% over 5 years and 80-87% over 10 years with transplanted anterior teeth with closed apices. Nethander<sup>(9)</sup> found 5-year success rates of over 90% for 68 mature teeth transplanted with a 2-stage technique. Josefsson<sup>(17)</sup> found 4-year success rates of 92% and 82% respectively for premolars with incomplete and complete root formation.

These consistently high success rates are a contrast to the variable results reported in many older studies. Schwartz and others<sup>(18)</sup> yielded success rates of only 76.2% at 5 years and 59.6% at 10 years. Similarly, Pogrel<sup>(19)</sup> found that his success rate for 416 autotransplanted teeth was 72%. However, other investigators of that era had more positive results. Kristerson,<sup>(20)</sup> for example, obtained a success rate of 93% when 100 autotransplanted premolars were observed for a mean of 6.3 years.

Although retention of the tooth and restoration of the edentulous space is the desired outcome for patients, more specific parameters have been used to measure the health of the surviving transplant. These parameters include marginal periodontal attachment, mobility, pain, root resorption, root development, sensitivity to percussion, gingival pocket depth, presence of gingivitis, and presence of fistulae.<sup>(9, 21)</sup> However, these studies are difficult to compare because each used different measures to determine success.

Contraindications of autogenous tooth transplantation include cardiovascular disease, poor oral hygiene, and lack of motivation and commitment on the part of the patient.<sup>(22)</sup> The patients taken in our study did not present with any cardiac problems and had good oral hygiene. When

the autotransplantation was first proposed, the benefits and risks of the technique were fully explained—the patient were motivated and agreed to comply with the treatment.

The most common cause of failure of the autotransplant is chronic root resorption.(23)More specifically, the causes of tooth loss following transplantation from most common to least common are inflammatory resorption, replacement resorption (ankylosis), marginal periodontitis, apical periodontitis, caries, and trauma.(18) Inflammatory resorption may become evident after 3 or 4 weeks, while replacement resorption may not become evident until 3 or 4 months after transplantation. The incidence of both types of resorption can be decreased with atraumatic extraction of the donor tooth and immediate transfer to the recipient site to minimize the risk of injury to the periodontal ligament.(8)

However, tooth transplantation is not recommended for patients with a multidentulous area, those who are prone to dental caries, those with poor oral hygiene, and those with systemic diseases contraindicative to surgery. A major problem of autotransplantation is that it requires an appropriate donor tooth. Ideally, a donor tooth should be (1) reasonably strong with good root volume and length, (2) easy for extraction, (3) not periodontally involved, etc. Surgical difficulties may be another problem in tooth transplantation. Unlike prefabricated implant devices, every tooth has a different size and shape. Therefore, it would be very useful if a technique can be developed to facilitate the recipient bone contouring or to provide standardized donor tooth by such as tissue engineering and genetic engineering.

As implant procedures become more popular, attention to natural tooth saving seems to diminish. However, we think that tooth autotransplantation is still a very useful method for replacing missing teeth, provided that the extraoral time and other factors are well controlled.

#### References:

1. Andreasen JO, Paulsen HU, Tou Z. A long-term study of 370 autotransplanted premolars. Part 2. Tooth survival and pulp healing subsequent to transplantation. *Eur J Orthodont* 1990; 12: 14–24.
2. Kallu R, Vinckier F, Politis C, Mwalili S, Willems G. Tooth transplantations: a descriptive retrospective study. *Int J Oral Maxillofac Surg* 2005;34:745-55.

3. Tsukiboshi M. Autogenous tooth transplantation: a re-evaluation. *Int J Periodont Rest Dent* 1993;13:120-49.

4. Paulsen HU, Zachrisson BU. Autotransplantation of teeth and orthodontic treatment planning. In: Andreasen JO, ed: *Atlas of replantation and transplantation of teeth*. Fibrourg: Mediglobe Co. 1992: 257–276.

5. Mejåre B, Wannfors K, Jansson L. A prospective study on transplantation of third molars with complete root formation. *Oral Surg Oral Med Oral Pathol Oral Radiol Endod* 2004;97:231-8.

6. Andreasen JO, Andreasen FM. *Textbook and color atlas of traumatic injuries to the teeth*. Copenhagen: Munksgaard; 1994.

7. Hale ML. Autogenous transplants. *Oral Surg Oral Med Oral Pathol* 1956; 9:76-83.

8. Cohen AS, Shen TC, Pogrel MA. Transplanting teeth successfully: autografts and allografts that work. *JADA* 1995; 126(4):481-5.

9. Nethander G. Periodontal conditions of teeth autogenously transplanted by a two-stage technique. *J Periodontal Res* 1994; 29:250-8.

10. Lundberg T, Isaksson S. A clinical follow-up study of 278 autotransplanted teeth. *Br J Oral Maxillofac Surg* 1996; 34:181-5.

11. Apfel H: Autoplasty of enucleated prefunctional third molars. *J Oral Surg*. 1950;8:289-96.

12. Apfel H: Preliminary work in transplanting the third molar to the first molar position. *J Am Dent Assoc*, 1954;48:143-50.

13. Fong CC: Transplantation of the third molar. *Oral Surg* 6917, 1953

14. Hale ML: Autoaenous transulants. *J Am Dent Assoc*. 1954; 49: 193-8.

15. Clark HB, Tam JC, Mitchell DF: Transplantation of developina teeth. *J Dent Res*. 1955; 34: 322-8.

16. Kugelberg R, Tegsjo U, Malmgren O. Autotransplantation of 45 teeth to the upper incisor region in adolescents. *Swed Dent J* 1994; 18:165-72.

17. Josefsson E, Brattstrom V, Tegsjo U, Valerius-Olsson H. Treatment of lower second premolar agenesis by autotransplantation: four-year evaluation of eighty patients. *Acta Odontol Scand* 1999; 57:111-5.

18. Schwartz O, Bergmann P, Klausen B. Autotransplantation of human teeth: a life-table analysis of prognostic factors. *Int J Oral Surg* 1985; 14:245-58.

19. Pogrel MA. Evaluation of over 400 autogenous tooth transplants. *J Oral Maxillofac Surg* 1987; 45:205-11.

20. Kristerson L, Lagerstrom L. Autotransplantation of teeth in cases with agenesis or traumatic loss of maxillary incisors. *Eur J Orthod* 1991; 13:486-92.

21. Andreasen JO, Paulsen HU, Yu Z, Bayer T. A long-term study of 370 autotransplanted premolars. Part IV. Root development subsequent to transplantation. *Eur J Orthod* 1990; 12:38-50.

22. Thomas S, Turner SR, Sandy JR. Autotransplantation of teeth: is there a role? *Br J Orthod* 1998;25:275-82.

23. Robinson PJ, Grossman LI. Tooth Transplantation. In: Robinson PJ, Guernsey LJ, eds. *Clinical transplantation in dental specialties*. St. Louis: C.V. Mosby Co.; 1980. p. 77-88.