

Unusual Occurrence of Multiple Supernumerary Teeth in Mixed Dentition in a Non Syndromic Patient: A Rare Entity (Case Report)

Deepak Passi¹, Geeta Singh², Laxman Malkunje², Gagan Mehta²

¹Department of Oral and Maxillofacial Surgery, Vyas Dental College & Hospital, Jodhpur, Rajasthan, India

²Department of Oral and Maxillofacial Surgery, Faculty of Dental Sciences, King George's Medical University, Lucknow, U.P., India

Address for Correspondence

Dr. Deepak Passi

Senior Lecturer,

Department of Oral and Maxillofacial Surgery

Vyas Dental College & Hospital

Jodhpur, Rajasthan, India

Ph – 9717299524

Email – drdeepakpassi@gmail.com

ABSTRACT

Hyperdontia or supernumerary teeth without associated syndrome are a rare phenomenon, as supernumerary teeth are usually associated with cleft lip and palate or other syndromes such as Gardner's syndrome and cleidocranial dysplasia. However it is rare to find multiple supernumeraries in individuals with no other associated disease or syndrome. We describe the occurrence of multiple supernumerary teeth in a family occurring as a non - syndromal trait. The autosomal dominant transmission of non-syndromal multiple supernumerary teeth are new.

Key words: Hyperdontia; Gardner syndrome; cleidocranial dysplasia; trichorhino phalangeic syndrome; Distomolar

INTRODUCTION

Supernumerary teeth or hyperdontia are the existence of an excessive number of teeth in relation to the normal dental formula, and they may develop at any location in either upper or lower dental arch. While single tooth impaction is not uncommon, development of multiple impacted teeth is a rare condition and often found in association with syndromes or developmental anomalies such as cleidocranial dysplasia, Gardner's syndrome, trichorhino phalangeic syndrome, and cleft lip and palate. However, it can be present in patients without any systemic pathology. The presence of supernumerary teeth can cause alterations in neighbouring teeth, commonly retained teeth or delayed eruption, ectopic eruption, dental malposition, occlusal problems, diastema, and rotation.

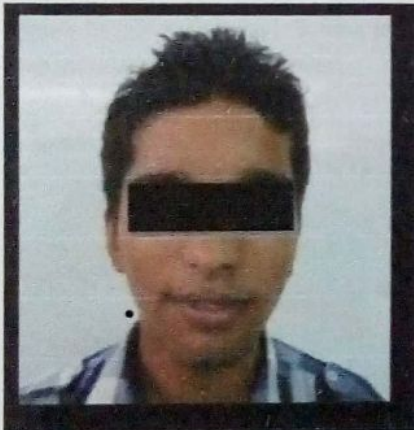

Figure 1: Profile view

CLASSIFICATION OF SUPERNUMERARY TEETH :

According to chronology, location (topography), morphology and their orientation. Chronologically, they can be classified as pre-deciduous, similar to

permanent teeth, and post permanent or complementary; Morphologically as conical, tuberculate, supplemental (eumorphic) and odontome; Topographically as mesiodens, paramolar, distomolar and parapremolar, and according to Orientation as vertical, inverted and transverse[8]. Paramolars are supernumerary molars, usually rudimentary (dysmorphic), situated buccally or lingually/palataly to the molar row. Mostly, they are situated between the second and third molars, while in very rare cases they can be found in between the first and second molars. Distomolars are situated either directly distal or distolingually to the third molar and are usually rudimentary conical shape.

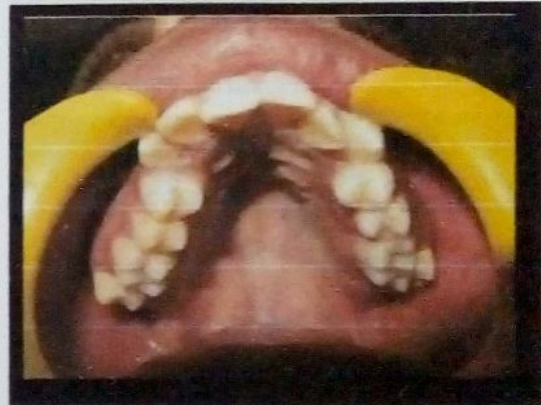

Figure 2(a) Intraoral view showing maxillary arch with slight crowding of teeth.

The exact **etiolog y** of the supernumerary teeth has not yet completely understood. Several theories have been suggested for their occurrence, such as the phylogenetic theory, the dichotomy theory, and occurrence due to hyperactive dental lamina and due to a combination of genetic and environmental factors. Generally, multiple supernumerary teeth are associated with diseases or syndromes.[4] Supernumerary teeth show strong association with

developmental disorders such as cleft lip and palate, cleidocranial dysostosis, Gardner syndrome and less commonly with Ehlers -Danlos syndrome, Fabry Anderson's syndrome, chondroectodermal dysplasia, incontinentia pigmenti and trichorhino -phalangeal syndrome.[2,5] .The autonomic recessive inheritance or linked to the X chromosome. Supernumerary teeth may erupt normally, remain impacted, appear inverted or assume an abnormal path of eruption.

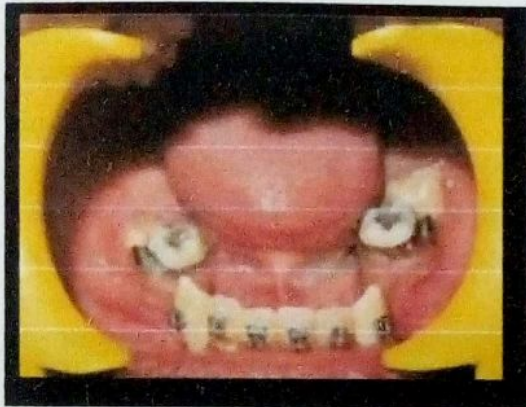


Figure 2 (b) Intraoral view showing mandibular arch with some clinically missing teeth.

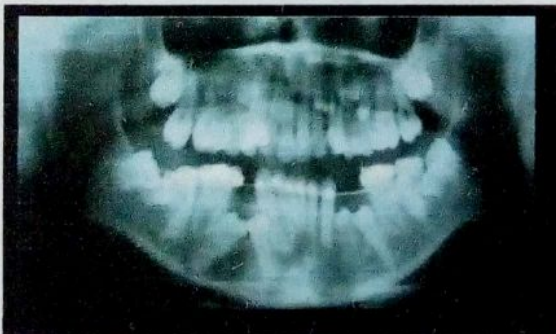

Figure 3. O.P.G showing multiple supernumerary teeth in maxillary premolar and mandibular molar region

CAS E REPORT

A 14 yr old boy reported to dept of oral and maxillofacial surgery with a chief complaint of irregular and missing teeth .patient was examined

through history, clinically and rad iographically with OPG and denta scan. Multiple supernumerary teeth were found in radiographic evaluation. **Family history was taken and was found to be non significant.** Orthodontic opinion was taken. Patient underwent extract ion of multiple supernumerary teeth and fixed orthodontic treatment.

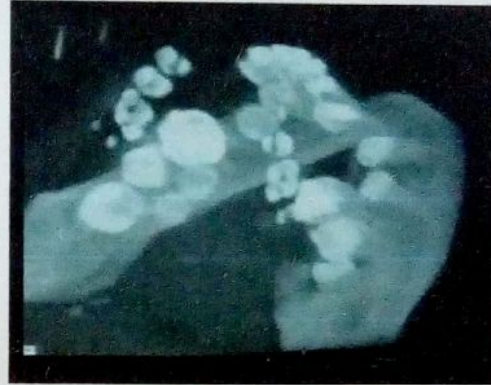


Figure 4(a) Denta scan showing supernumerary teeth in left mandibular molar region

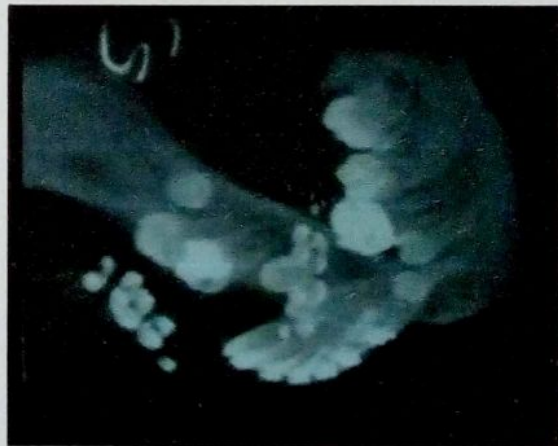

Figure 4(b) Denta scan showing supernumerary tooth in right mandibular molar region

DISCUSS ION

Supernumerary paramolars are the rare anomalies of the maxillofacial complex. Supernumerary teeth are defined as those in addition to the normal series of deciduous or permanent dentition. They may occur anywhere in the mouth. They may appear as a single

tooth or multiple teeth, unilaterally or bilaterally, erupted or impacted and in mandible/ maxilla or both the jaws. The prevalence of supernumerary teeth varies between 0.1 and 3.8% and is more common in the permanent dentition.[1-3] The low prevalence of supernumerary teeth in primary dentition is because it is generally overlooked by the parents, is often of normal shape (supplemental type), erupt normally, and appear to be in proper alignment.[4]

The incidence is considerably higher in the maxillary incisor region followed by maxillary third molar and mandibular molar, premolar, canine and lateral incisors.[5] Though there is no significant sex distribution in primary supernumerary teeth, males are affected approximately twice than females in the permanent dentition.[6,7]

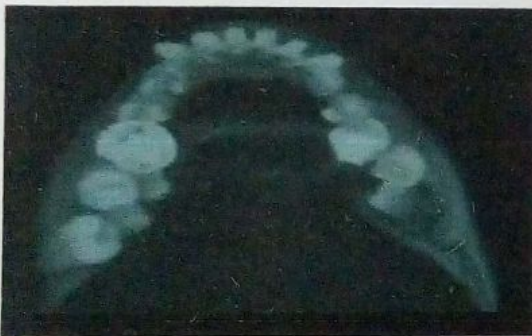

Figure 5. Occlusal view showing supernumerary teeth in right and left mandibular molar region

Supernumerary teeth are found in association with syndromes or developmental anomalies such as cleidocranial dysplasia, Gardner's syndrome, trichorhino phalangic syndrome, and cleft lip and palate. However, it can be present in patients without any systemic pathology. The frequency of supernumerary permanent teeth in the cleft area in children with unilateral cleft lip or palate or both was found to be 22.2%.[12,13,14,15] The frequency of

supernumeraries in patients with cleidocranial dysplasia ranged from 22% in the maxillary incisor region to 5% in the molar region.

Complications associated with supernumerary teeth may be delay or failure of eruption of permanent teeth, displacement, crowding, root resorption, dilaceration, loss of vitality of adjacent teeth, subacute pericoronitis, gingival inflammation, periodontal abscesses, dental caries due to plaque retention in inaccessible areas, incomplete space closure during orthodontic treatment, and pathological problems such as dentigerous cyst formation, ameloblastomas, odontomas and fistulae. They may also interfere in alveolar bone grafting and implant placement.

Occasionally, supernumerary teeth are asymptomatic and may be detected as a chance finding during radiographic examination. Detailed history, clinical examination, thorough investigation, early diagnosis and appropriate treatment of supernumerary teeth are mandatory. An anterior occlusal or periapical radiograph using paralleling technique and panoramic view (OrthoPantomograph) are the most useful radiographic investigations to visualize supernumerary teeth. Recently computed tomography has also been used to detect the presence of supernumerary teeth. [9,10,11] Treatment depends on the type and location of the supernumerary teeth and on its potential effect on adjacent hard and soft tissue structures. Removal of the supernumerary teeth is recommended where there is associated pathology, permanent tooth eruption has been delayed due to the presence of supernumerary tooth, increased risk of caries due to the presence of supernumerary teeth which makes the area inaccessible to maintain oral hygiene, altered eruption or displacement of adjacent

tooth is evident, there are severely rotated teeth leading to further complication, orthodontic treatment needs to be carried out to align the teeth, its presence would compromise alveolar bone grafting and implant placement and there is compromised esthetic and functional status.

CONCLUSION

Supernumerary teeth can present in any region of oral cavity. Multiple supernumerary teeth are a feature of certain disorders like cleidocranial dysplasia, cleft Palate, and Gardner's syndrome. Detection of these teeth is best achieved by clinical and radiographic examination. These may erupt or remain impacted and may lead to various complications. Though the occurrence of paramolars is rare, clinicians should be aware of their presence and associated problems in order to formulate a sound treatment plan after thorough clinical and radiographic investigations, to meet the challenges.

REFERENCES

1. Yusof WZ. Non-syndromal multiple supernumerary teeth: Literature review. *J Can Dent Assoc.* 1990;56:147-9. [[PubMed ed](#)]
2. Rajab LD, Hamdan M A. Supernumerary teeth: Review of the literature and a survey of 152 cases. *Int J Pediatr Dent.* 2002;12:244-54. [[PubMed ed](#)]
3. Brook AH. Dental anomalies of number, form and size: Their prevalence in British school children. *J Int Assoc Dent Child.* 1974;5:37-53. [[PubMed ed](#)]
4. Scheiner M A, Sampson WJ. Supernumerary teeth: A review of the literature and four case reports. *Aus Dent J.* 1997;42:160-5. [[PubMed ed](#)]
5. Grimanis GA, Kyriakides AT, Spyropoulos ND. A survey on supernumerary molars. *Quintessence Int.* 1991;22:989-95. [[PubMed ed](#)]
6. Kinirons M J. Unerupted premaxillary supernumerary teeth. A study of their occurrence in males and females. *Br Dent J.* 1982;153:110. [[PubMed ed](#)]
7. Garvey MT, Barry HJ, Blake M. Supernumerary teeth- an overview of classification, diagnosis and management. *J Can Dent Assoc.* 1999;65:612-6. [[PubMed ed](#)]
8. Shah A, Gill DS, Tredwin C, Naini FB. Diagnosis and management of supernumerary teeth. *Dental Update.* 2008;35:510-20. [[PubMed ed](#)]
9. Liu DG, Zhang WL, Zhang ZY, Wu YT, Ma XC. Three dimensional evaluations of supernumerary teeth using cone-beam computed tomography for 487 cases. *Oral Surg Oral Med Oral Pathol Oral Radiol Endod.* 2007;103:403-11. [[PubMed ed](#)]
10. Ballal S, Sachdeva GS, Kandaswamy D. Endodontic management of a fused mandibular second molar and premolar with the aid of spiral computed tomography: A case report. *J Endod.* 2007;35:1247-51. [[PubMed ed](#)]
11. Loh FC, Yeo JF. Paramolar with bifid crown. *Oral Surg Oral Med Oral Pathol Oral Radiol.* 1993;76:257-8. [[PubMed ed](#)]
12. Ghoddsi J, Zarei M, Jafarzadeh H. Endodontic treatment of a supernumerary tooth fused to a mandibular second molar: A case report. *J Oral Sci.* 2006;48:39-41. [[PubMed ed](#)]
13. Nunes E, De Moraes IG, De Novaes PM, De Sousa SM. Bilateral fusion of mandibular second molars: A case report. *Braz Dent J.* 2002;13:137-41. [[PubMed ed](#)]
14. Rao PV, Chidzonga MM. Supernumerary teeth: literature review. *Cent Afr J Med.* 2001;47:22-26. [[PubMed ed](#)]
15. Jensen BL, Kreiborg S. Development of the dentition in cleidocranial dysplasia. *J Oral Pathol Med.* 1990; 19:89-93.